

Thoracic-A Format-A

Niels F. Jensen, MD

Copyright 2000: Ranger Red-Oral Board P.R.E.P. Cases and Tapes

The Best Medicine for Your Oral Boards

Phone: 319-337-3700

General Instructions

1. Read the question X 2.
2. Outline the question in 2 minutes.
3. Take the test, recording responses if possible. If you are self-testing, read the question and then answer. If you are tested by someone else, have them read the question and then answer.
4. Compare your outline to mine.
5. Compare your answers to mine, on paper (section D) and tape (tape set 3 of 3).

Outlining Drill: Ranger attack!

A 56 year-old, 70 Kg, 5'8" tall male is brought to the operating room for a left upper lobectomy.

HPI: Patient noted the onset of a productive cough 6 weeks ago and an episode of hemoptysis 10 days ago. He was seen by a pulmonary specialist who noted a 2 cm mass in his left upper lobe on chest x-ray. Fiberoptic bronchoscopy revealed irregularity of the left upper lobe bronchus, and biopsy revealed carcinoma. Metastatic workup was negative.

PMH: Uncomplicated myocardial infarction 4 months ago. He notes angina with exercise over the past month. A stress test 7 days ago showed minimal ST segment depression at a heart rate of 120 beats per minute without angina. An echocardiogram revealed an ejection fraction of 55%.

Medications include diltiazem and nitroglycerin PRN. He has no allergies. He smoked 2 packs of cigarettes per day for 25 years until 10 days ago. He drinks an occasional beer.

Phys. Exam: P 72, BP 140/80, R 20, T 37.1° C. His airway appears normal. Chest auscultation reveals expiratory wheezes over left posterior upper lung field. Cardiac exam is normal. He has no organomegaly or peripheral edema.

Chest X-Ray: 2 cm mass and small infiltrate left upper lobe.

EKG: Q waves in II, III, aVf with T wave inversion in same leads.

Lab Studies: Hgb 14.5 gms/dl, normal electrolytes and normal coagulation studies.

He arrives in operating room at 10:00 AM with 1" nitropaste, having taken his diltiazem at 7:00 AM.

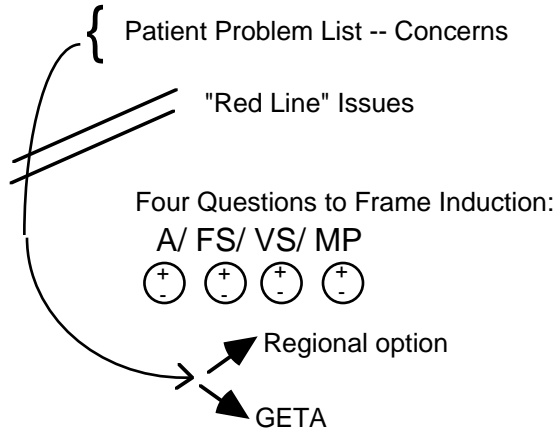
Specific Instructions: Outlining drill
 Below is the grid for the two minute outlining drill. The full five minute drill and complete instructions for outlining can be found in the Outlining chapter of Big Red and Ranger Red. Time yourself.

Two Minute Outlining Drill

Read Question x 2

Emergency?

Why?



1. Concerns	2. How	3. Drugs
From Above	IV-IM Inhalation Awake Trach	In order given, including relaxant Avoid giving drug doses

OUTLINE BELOW

In the space provided, please outline this case in two minutes. Stop after this time and assess progress. The Corporal should formulate a problem list, identify any "Red line" issues, conceptualize the induction of anesthesia and formulate wording. Full instructions for outlining a stem question can be found in the Outlining chapter of Big Red and Ranger Red. The stem question in the first room can be long and involved. Outlining is a critical skill to organize information and formulate plans. Again, the case:

A 56 year-old, 70 Kg, 5'8" tall male is brought to the operating room for a left upper lobectomy.

HPI: Patient noted the onset of a productive cough 6 weeks ago and an episode of hemoptysis 10 days ago. He was seen by a pulmonary specialist who noted a 2 cm mass in his left upper lobe on chest x-ray. Fiberoptic bronchoscopy revealed irregularity of the left upper lobe bronchus, and biopsy revealed carcinoma. Metastatic workup was negative.

PMH: Uncomplicated myocardial infarction 4 months ago. He notes angina with exercise over the past month. A stress test 7 days ago showed minimal ST segment depression at a heart rate of 120 beats per minute without angina. An echocardiogram revealed an ejection fraction of 55%.

Medications include diltiazem and nitroglycerin PRN. He has no allergies. He smoked 2 packs of cigarettes per day for 25 years until 10 days ago. He drinks an occasional beer.

Phys. Exam: P 72, BP 140/80, R 20, T 37.1° C. His airway appears normal. Chest auscultation reveals expiratory wheezes over left posterior upper lung field. Cardiac exam is normal. He has no organomegaly or peripheral edema.

Chest X-Ray: 2 cm mass and small infiltrate left upper lobe.

EKG: Q waves in II, III, aVf with T wave inversion in same leads.

Lab Studies: Hgb 14.5 gms/dl, normal electrolytes and normal coagulation studies.

He arrives in operating room at 10:00 AM with 1" nitropaste, having taken his diltiazem at 7:00 AM.